

Combined Use of Skin Needling and Platelet-Rich Plasma in Acne Scarring Treatment

Gabriella Fabbrocini, MD; Valerio De Vita, MD; Francesco Pastore, MD; Luigia Panariello, MD; Nunzio Fardella, MD; Rossana Sepulveres, MD; Elio D'Agostino, MD; Norma Cameli, MD; Antonella Tosti, MD

Platelet-rich plasma (PRP) contains autologous growth factors, which could act synergistically with growth factors induced by skin needling in order to enhance the wound-healing response. The combination of treatments, carried out by using skin needling and PRP application, should enhance both efficacy of skin needling and PRP application. The objective of this study is to establish the effectiveness of the combined use of skin needling and PRP application in acne scarring treatment. Twelve patients affected with rolling acne scars were enrolled. Each patient underwent 2 sessions of treatments, each consisting of skin needling followed by PRP application on the right side of the face and skin needling alone on the left side of the face. Digital photographs of all patients were taken. Photographic data were analyzed by using the Sign Test ($\alpha < .05$). The study showed that the scars severity grade in all patients was greatly reduced on all of the face, but the improvement was more efficient on the side treated with both skin needling and PRP. Our study showed that the combined use of skin needling and PRP is more effective than skin needling alone in improving acne scars.

Acne can produce permanent scars that are difficult to treat. Recently, it was reported that skin needling is an appropriate treatment for rolling acne scars.¹ This procedure induces the deposition of new

collagen in the upper dermis² and provides a clear channel for topical agents to be absorbed more effectively through the top layer of skin. Platelet-rich plasma (PRP) contains autologous growth factors, especially epidermal growth factor, platelet-derived growth factor, transforming growth factor β and vascular endothelial growth factor, that act synergistically with growth factors induced by skin needling in order to enhance the wound-healing response.^{3,4} It has been reported that the concentrations of these growth factors in PRP are several times higher than in normal plasma.^{5,6} Platelet-rich plasma is used in many areas of medicine, including the acceleration of healing of tendon injuries, the treatment of osteoarthritis, in some dental procedures, and in cardiovascular medicine. The concentrated form of plasma has been shown to accelerate wound healing and tissue repair, and therefore

Drs. Fabbrocini, De Vita, Pastore, Panariello, and Fardella are from the Department of Systematic Pathology, Division of Clinical Dermatology, and Drs. Sepulveres and D'Agostino are from the Department of Cellular and Molecular Biology and Pathology, University of Naples Federico II, Italy. Dr. Cameli is from San Gallicano Dermatologic Institute, Rome, Italy. Dr. Tosti is from the Department of Internal Medicine, Geriatrics and Nephrology, Division of Dermatology, University of Bologna, Italy.

The authors report no conflict of interest in relation to this article.

Correspondence: Gabriella Fabbrocini; MD (gafabbro@unina.it).

treatment of scars. The combination of skin needling and PRP application might enhance the efficacy of both procedures. The aim of the present study was to compare effectiveness in acne scarring treatment of the combined use of skin needling and PRP versus skin needling alone.

MATERIALS AND METHODS

This study was conducted at the University of Naples Federico II, Department of Systematic Pathology, Division of Dermatology. In total, 12 patients were included (7 women, 5 men; age range, 18–45 years; mean age, 32.2 years). The study was approved by the ethical committee of the IFO Institute. Exclusion criteria are listed in Table 1.

Preparation of Platelet-Rich Plasma

Platelet-rich plasma is a product of blood-processing, resulting from the activation of the mix of 2 traditional blood components: platelet concentrate (PC) and cryoprecipitate. It is obtained by the following method: first, 70 to 80 mL of autologous whole blood is collected into tubes containing acid-citrate-dextrose (ACD) and centrifuged at 1200 g for 15 minutes in order to get PRP at the top of the test tube. Then, the PRP is further centrifuged at 1800 g for 10 minutes in order to obtain a PC with a platelet count 4.5 times higher than the baseline, and a platelet-poor plasma (PPP); the PPP is partly removed and partly used to resuspend the platelets. The PC is preserved in a sterile container and then combined with human thrombin (0.2 ml per mL of PC) and calcium gluconate. The gel is ready to be used after 7 to 10 minutes at room temperature or at 37°C.

Treatment

Before the first treatment began, the severity of lesions in each patient was scored on a 10-point scale (0=no lesions; 10=maximum severity). For each side of a patient’s face, digital photographs were taken and filed in a database. After disinfection, a topical anesthetic (lidocaine 2.5% and prilocaine 2.5%) was applied for 60 minutes. Skin needling was carried out by using a rolling barrel 10-mm wide, equipped with 96 needles in 4 rows. The needles used were 1.5 mm long and 0.25 mm in diameter. Depending on the applied pressure, needles penetrate the scar tissue between 0.1 and 1.3 mm. Needling was sequentially performed over the affected areas for a total of 10 to 14 passes in 4 directions: horizontally, vertically, diagonally right to left, and diagonally left to right. The left side of the face was treated by the needling technique alone; the right side of the face was first treated with PRP and needling (Figure 1). First, 0.2 to 0.3 cc of PRP was applied on the treated area and

TABLE 1

Main Skin Needling Exclusion Criteria

- Personal history of keloid scarring
- Diabetes
- Neuromuscular disease
- Bleeding disorder
- Collagen vascular disease
- Acute or chronic corticosteroid therapy
- Acute or chronic anticoagulant therapy
- Presence of skin cancers
- Warts
- Solar keratoses
- Skin infection
- Pregnancy

needling was then immediately performed as described above. Each patient underwent a follow-up visit 1 week after the procedure in order to evaluate side effects.

A second session of treatment was performed 8 weeks later using the same procedure. The final follow-up visit was conducted 32 weeks after the second treatment. At this time the degree of improvement was evaluated by digital photographs and scar severity score.

Statistical Analysis

Digital photographic data were statistically analyzed by using a test for nonparametric data, the Sign Test for paired data. The null and alternative hypotheses are: differences’

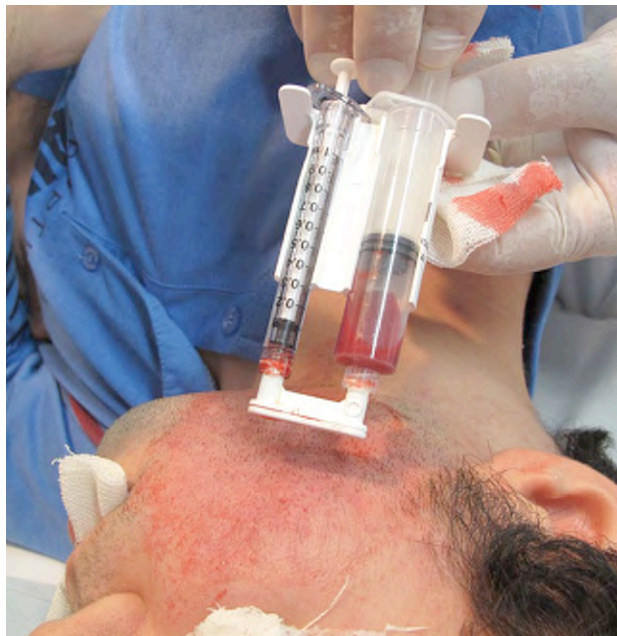

Figure 1. Platelet-rich plasma application.

median is zero [$P(+)=P(-)$]; and differences' median is negative [$P(+)<P(-)$] ($\alpha=.05$). The result is calculated by computing the binomial probability.

RESULTS

All patients completed the study. No adverse effects, including hyperpigmentation, were observed. After each session of treatment, patients' facial skin on both sides appeared red and swollen, but in all cases redness and swelling disappeared in 2 to 3 days.

At the end of the study, the photographic comparison highlighted that, independently of severity of lesions, the relative rolling scar depth was significantly reduced (Figures 2–5). The Sign Test for paired data ($P<.05$) highlights that the differences' median is negative, showing that the reduction of severity grade of acne scars, after skin needling alone or skin needling combined with PRP, should be considered statistically significant.

Severity score analysis showed that acne scars on right side of patients' faces, treated with skin needling in combination with PRP application, had higher improvement than the ones on the left side, treated with skin needling alone (Table 2).

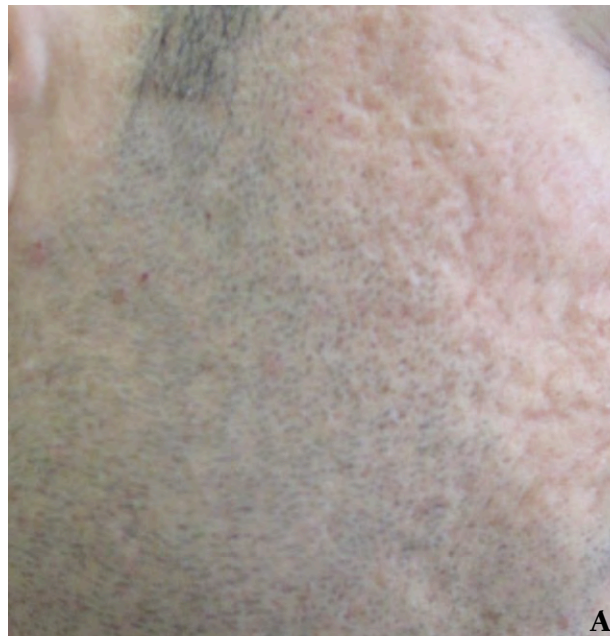
COMMENT

Since 1995, skin needling has been used to achieve percutaneous collagen induction in order to reduce skin imperfection.² To date, skin needling has mostly been proposed as an effective method of treating scars and

wrinkles.^{1,7,8} Microneedles penetrate through the epidermis, which is only punctured and heals rapidly because this technique only produces contained tissue damage, as opposed to ablative lasers, which vaporize and destroy epidermis and superficial dermis.⁹

The epidermis, and particularly the stratum corneum, remains intact except for the minute holes, which are about 4 cells in diameter.² Skin needling efficacy depends on its capacity to induce the neocollagenogenesis and the wound-healing process in the upper dermis. Skin needling triggers a cascade of growth factors that directly stimulate the maturation phase of wound healing, provoking the healing process and increasing the skin repair events.¹⁰⁻¹² Furthermore, skin needling provides a clear channel for topical agents to be absorbed more effectively through the top layer of skin such as the PRP.¹³ Platelet-rich plasma contains autologous growth factors, which could act synergistically with growth factors induced by skin needling in order to enhance the wound-healing response. Platelets, once activated, release several growth factors, cytokines, and chemokines, including vascular endothelial growth factor, platelet-derived growth factor, epidermal growth factor, fibroblast growth factor, transforming growth factor- β (TGF- β), insulinlike growth factor, IL-8, macrophage inflammatory protein-1 α (MIP-1 α), and platelet factor 4.

The ability of skin needling to create a way for PRP absorption and the ability of platelets to contribute to wound healing induced by skin needling are the



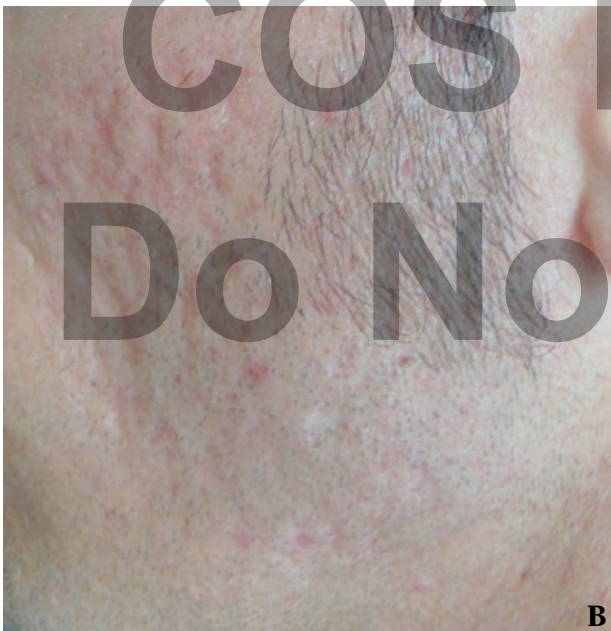
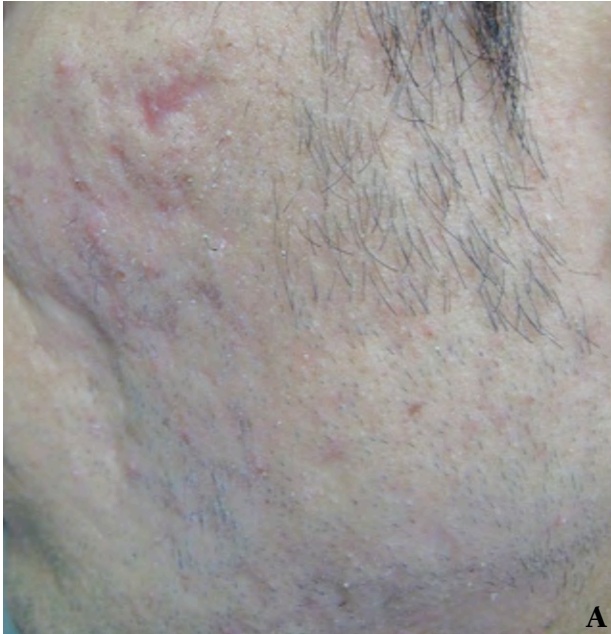COS DERM
Do Not Copy

Figure 2. Right side of a patient's face before treatment with skin needling and platelet-rich plasma (PRP)(A). Right side of the patient's face after treatment with skin needling and PRP (B).

basis of the theoretical use of PRP in combination with skin needling.

Skin needling is a minimally invasive procedure with rapid healing and little downtime. It has undisputable advantages with respect to other techniques available for the treatment of acne scars; the most important is that a portion of the epidermis remains intact because it is not damaged. This avoids most

possible adverse effects observed after chemical peeling or laser resurfacing. As melanocytes are not directly targeted, risks of postinflammatory hypo- or hyperpigmentation are minimal. Despite this fact, according to our experience, an adequate photoprotection (SPF 50+) is necessary within 7 days after the treatment. This procedure can then be safely performed on the skin of people of Asian descent and darker skin tones, as well



COSDERM
Do Not Copy

Figure 3. Left side of a patient's face before treatment with skin needling alone (A). Left side of the patient's face after treatment with skin needling alone (B).

as on skin that has been previously treated with lasers or dermabrasion.

Recent studies using microarray analysis showed that needling upregulates expression of TGF- β 3, which is an essential marker for preventing scarring.¹⁴⁻¹⁷ In fact, the isoforms TGF- β 1 and TGF- β 2 have profibrotic properties, while TGF- β 3 may have antifibrotic functions. In tissue samples with normal fibroblasts serving as

control samples, expression of TGF- β 1 and TGF- β 2 was decreased when compared to keloid fibroblasts, while expression of TGF- β 3 and of TGF- β 2 was significantly ($P < .05$) higher in normal fibroblasts.¹⁸

Similarly to skin needling, the fractional laser also stimulates the neocollagenogenesis and the wound-healing process in the upper dermis, with the production of several growth factors. This kind of laser is

TABLE 2

Acne Scarring Severity Scores

Patient	Left Side (Skin Needling Only) Pretreatment	Left Side (Skin Needling Only) Follow-up, wk 32	Right Side (Skin Needling and PRP) Pretreatment	Right Side (Skin Needling and PRP) Follow-up, wk 32
1	7	6	7	5
2	9	6	9	5
3	8	5	8	5
4	6	3	6	2
5	8	5	8	4
6	8	5	8	4
7	6	4	6	4
8	7	4	7	3
9	10	6	10	5
10	7	5	7	4
11	6	3	6	2
12	8	7	8	5
Mean Value	7.5	4.9	7.5	4

Abbreviation: PRP, platelet-rich plasma.

a 30 W, diode-pumped, 1550-nm erbium fiber laser that targets water as its chromophore. The Fraxel laser coagulates epidermal and dermal tissue; the coagulated tissue is expelled and replaced by keratinocyte migration. Zones of collagen denaturation in the dermis cause upregulation of the inflammatory cascade, which leads to collagen remodeling and new collagen formation.^{19,20}

Therefore, this study confirms the efficacy of skin needling in acne scarring treatment and suggests that the combined use of skin needling and PRP is more effective in improving acne scars than skin needling alone. It represents an interesting tool for further in-depth research and additional experimentation on the use of PRP in association with other techniques, such as the

Fraxel laser, which also stimulates the wound-healing process, collagen remodelling, and new collagen formation through the induction of growth factor synthesis.

REFERENCES

1. Fabbrocini G, Fardella N, Monfrecola A, et al. Acne scarring treatment using skin needling. *Clin Exp Dermatol*. 2009;34:874-879.
2. Fernandes D. Minimally invasive percutaneous collagen induction. *Oral Maxillofac Surg Clin North Am*. 2005;17:51-63.
3. Everts PA, Jakimowicz JJ, van Beek M, et al. Reviewing the structural features of autologous platelet-leukocyte gel and suggestions for use in surgery. *Eur Surg Res*. 2007;39:199-207.
4. Hom DB, Linzie BM, Huang TC. The healing effects of autologous platelet gel on acute human skin wounds. *Arch Facial Plast Surg*. 2007;9:174-183.
5. Eppley BL, Woodell JE, Higgins J. Platelet quantification and growth factor analysis from platelet-rich plasma: implications for wound-healing. *Plast Reconstr Surg*. 2004;114:1502-1508.
6. Weibrich G, Kleis WK, Hafner G, et al. Growth factor levels in platelet-rich plasma and correlations with donor age, sex, and platelet count. *J Craniomaxillofac Surg*. 2002;30:97e102.
7. Fabbrocini G, De Padova MP, De Vita V, et al. Trattamento de ruga periorbitais por terapia de inducao de colageno[article in Portuguese]. *Surg Cosmet Dermatol*. 2009;1:106-111.
8. Aust MC, Reimers K, Gohritz A, et al. Percutaneous collagen induction. scarless skin rejuvenation: fact or fiction? *Clin Exp Dermatol*. 2010;4:437-439.
9. Fabbrocini G, Annunziata MC, D'Arco V, et al. Acne scars: pathogenesis, classification and treatment. *Dermatology Res Pract*. 2010;2010:893080.
10. Robinson KR. The responses of cells to electrical fields: a review. *J Cell Biol*. 1985;101:2023-2027.
11. Ojingwa JC, Isseroff RR. Electrical stimulation of wound-healing. *J Invest Dermatol*. 2003;121:1-12.
12. Jaffe L. Control of development by steady ionic currents. *Fed Proc*. 1981;40:125-127.
13. Fabbrocini G, De Vita V, Pastore F, et al. The use of skin needling for eutectic mixture of local anesthetics delivery. *Dermatologic Therapy*. 2011;in press.
14. McAllister DV, Wang PM, Davis SP, et al. Microfabricated needles for transdermal delivery of macromolecules and nanoparticles: fabrication methods and transport studies. *Proc Natl Acad Sci USA*. 2003;100:13755-13760.
15. Teo AL, Shearwood C, Ng KC, et al. Transdermal microneedles for drug delivery applications. *Mater Sci Eng B*. 2006;132:151-154.
16. Banks SL, Pinninti RR, Gill HS, et al. Flux across of microneedle-treated skin is increased by increasing charge of naltrexone and naltrexol in vitro. *Pharm Res*. 2008;25:1677-1685.
17. Mitragotri S. Synergistic effect of enhancers for transdermal drug delivery. *Pharm Res*. 2000;17:1354-1359.
18. Bran GM, Goessler UR, Schardt C, et al. Effect of the abrogation of TGF-beta1 by antisense oligonucleotides on the expression of TGF-beta-isoforms and their receptors I and II in isolated fibroblasts from keloid scars. *Int J Mol Med*. 2010;25:915-921.
19. Tanzi EL, Wanitphakdeedecha R, Alster TS. Fraxel laser indications and long-term follow-up. *Aesthet Surg J*. 2008;28:675-678.
20. Collawn SS. Fraxel skin resurfacing. *Ann Plast Surg*. 2007;58:237-240. ■

Do Not Copy