

ORIGINAL ARTICLE

The effect of CD34+ cell-containing autologous platelet-rich plasma injection on pattern hair loss: a preliminary study

J.-S. Kang,¹ Z. Zheng,² M.J. Choi,² S.-H. Lee,² D.-Y. Kim,² S.B. Cho^{2,*}

¹Kangskin Clinic and ²Department of Dermatology and Cutaneous Biology Research Institute, Yonsei University College of Medicine, Seoul, Korea

*Correspondence: S.B. Cho. E-mail: sbcho@yuhs.ac

Abstract

Background Mobilized CD34+ cells in peripheral blood have angiogenic potential, which is an important factor in active hair growth. In addition, activated autologous platelet-rich plasma (PRP) has been reported to induce the proliferation of dermal papilla cells.

Objectives To investigate the clinical efficacy of interfollicular injection of CD34+ cell-containing PRP preparation for pattern hair loss.

Patients and methods CD34+ cell-containing PRP preparation was injected on the scalps of 13 patients with pattern hair loss, and 13 patients were treated with interfollicular placental extract injection as a control. The numbers of platelets in PRP were microscopically counted and CD34+ cells were evaluated with flow cytometry.

Results Three months after the first treatment, the patients presented clinical improvement in the mean number of hairs, $20.5 \pm 17.0\%$ ($P < 0.0001$), mean hair thickness, $31.3 \pm 30.1\%$ ($P < 0.0001$), and mean two-point score, $84.4 \pm 51.7\%$ ($P < 0.0001$) compared with baseline values. At 6 months, the patients presented clinical improvement in mean hair count, $29.2 \pm 17.8\%$ ($P < 0.0001$), mean hair thickness, $46.4 \pm 37.5\%$ ($P < 0.0001$), and mean two-point score, $121.3 \pm 66.8\%$ ($P < 0.0001$) compared with baseline. The MIXED procedure revealed that CD34+ cell-containing PRP treatment presented a higher degree of improvement than placental extract treatment in hair thickness ($P = 0.027$) and overall clinical improvement ($P = 0.023$).

Conclusion Our data suggest that the interfollicular injection of autologous CD34+ cell-containing PRP preparation has a positive therapeutic effect on male and female pattern hair loss without remarkable major side-effects.

Received: 24 August 2012; Accepted: 08 November 2012

Conflicts of interest

The authors have declared no conflicts of interest.

Funding Sources

None.

Introduction

Platelet-rich plasma (PRP) has been used to promote wound healing processes in hard and soft tissues in various medical conditions.^{1–5} Prepared plasma contains highly concentrated platelets and releases numerous proteins composed of growth factors, chemokines and cytokines in platelet α -granules, which stimulate cell proliferation and differentiation.^{2–4} In addition, the role of PRP for the treatment of pattern hair loss has been demonstrated in recent reports.^{1,2,6} Uebel *et al.*⁶ demonstrated that follicular unit implantation with patients' autologous PRP resulted in a higher yield of follicular units. Activated autologous PRP has been reported to induce the proliferation of dermal papilla cells by

up-regulating fibroblast growth factor 7 (FGF-7) and β -catenin as well as extracellular signal-related kinase (ERK) and Akt signalling.²

Anagen-associated angiogenesis has been suggested as one of the important factors in active hair growth.⁷ In addition, the angiogenic factor of vascular endothelial growth factor (VEGF) also originated from the keratinocytes in the outer root sheath and fibroblasts in dermal papilla.^{7–9} Therefore, the currently available treatment modalities for pattern hair loss have been shown to modulate angiogenesis and enhance blood flow.¹⁰ Injection of PRP has been demonstrated to improve cutaneous ischaemic conditions and to increase vascular structures around hair follicles.^{1,11}

Bone marrow-derived CD34+ haematopoietic stem cells have shown beneficial effects in inflammatory and non-inflammatory diseases by promoting angiogenesis and/or vasculogenesis, especially in conditions of myocardial ischaemia.^{12,13} However, it has been suggested that the mobilized CD34+ cells in peripheral blood naturally decrease in the number of circulating cells and lose angiogenic potential with age.¹² As α -granules in PRP include platelet-derived angiogenesis factor, platelet-derived endothelial growth factor and VEGF,⁴ we hypothesized that the clinical application of CD34+ cells in autologous PRP preparation can be effectively used for the treatment of male and female pattern hair loss.

Patients and methods

Patients

A total of 15 male patients (mean age: 36.1; age range: 26–62) with male pattern hair loss and 11 female patients (mean age: 38.7; age range: 22–55) with female pattern hair loss were reviewed in this study. The patient characteristics are summarized in Table 1. Patients, who had undergone concomitant treatments, including topical medications (such as minoxidil, alphatradiol, prostaglandin analogues, retinoids, melatonin and corticosteroid), oral medications (such as finasteride, dutasteride and antiandrogens), mesotherapy, non-ablative fractional laser treatment, low-level laser therapy, interfollicular PRP injection and hair transplantation, within the preceding 6 months were excluded. Patients with a propensity for keloids and patients who were immunosuppressed were also excluded. In addition, the numbers of platelets in PRP obtained from all participants were microscopically counted. This study was approved by the Institutional Review Board of Severance Hospital, Yonsei University College of Medicine, Seoul, Korea.

Treatment protocol

CD34+ cell-containing PRP was prepared using SmartPreP[®]2 APC+TM (Harvest Technologies Corp., Plymouth, MA, USA) in participants ($n = 13$; seven males and six females; mean age: 37.6; age range: 22–62) who provided informed consent. Briefly, 60 mL of blood obtained from the participants was transferred to tubes containing 8 mL of 4% sodium citrate solution (Baxter Healthcare Corp., Deerfield, IL, USA). Then, the blood was centrifuged with the SmartPreP[®]2 platelet concentrate system (Harvest Technologies Corp.). The scalp was cleansed with 70% alcohol, and local anaesthesia of 2% lidocaine with 1 : 100 000 epinephrine (3–5 mL) was injected on the frontal and parietal areas. Then, CD34+ cell-containing PRP preparation (4 mL) was injected on the scalp at the amount of 0.05–0.1 mL/cm². Interfollicular injection of CD34+ cell-containing PRP preparation was performed twice with a 3-month interval.

The second group of patients ($n = 13$; eight males and five females; mean age: 36.8; age range: 26–47) was treated with interfollicular placental extract injection. Placental extracts are enriched in bioactive molecules, including growth factors, amino acids, nucleic acids, vitamins, fatty acids and minerals, and have been used for various purposes.^{14–17} The scalp was cleansed with 70% alcohol, and 2 mL of placental extract (Melsmon[®]; Melsmon Pharmaceutical Co., Ltd., Tokyo, Japan) was injected on the frontal and parietal areas without local anaesthesia.¹⁸ During the treatment, a cooling device with cold air (–10 °C; Zimmer MedizinSystems, Irvine, CA, USA) was briefly used to relieve pain. The placental extract was delivered to the patients at 1-week intervals for 6 months. Concomitant treatment of 1 mg of oral finasteride was initiated in male patients, which are summarized in Table 1. All of the participants in both groups were advised to avoid the use of topical medications (such as minoxidil,

Table 1 Baseline patient demographic and clinical characteristics

Platelet-rich plasma (PRP) preparation treatment					Placental extract treatment			
Pt.	Sex/age	Concomitant treatment	Baseline two-point score	Platelet concentration of PRP preparation (platelets/ μ L)	Pt.	Sex/age	Concomitant treatment	Baseline two-point score
1	M/52	Finasteride	25.3	1 826 000	1	M/31	Finasteride	25.9
2	M/30	Finasteride	27.6	1 565 000	2	M/31	Finasteride	34.2
3	M/25	Finasteride	35.3	1 445 000	3	F/55	–	23.7
4	F/22	–	26.3	1 204 000	4	M/28	Finasteride	27.1
5	M/34	Finasteride	24.4	1 363 000	5	M/31	Finasteride	33.6
6	M/42	Finasteride	47.9	1 013 000	6	M/35	Finasteride	44.4
7	M/62	Finasteride	30.3	1 131 000	7	M/44	Finasteride	25.2
8	M/26	Finasteride	26.7	1 911 000	8	M/33	Finasteride	13.4
9	F/33	–	7.8	1 932 000	9	F/37	–	10.4
10	F/48	–	21.3	1 879 000	10	F/39	–	8.6
11	F/54	–	9.9	1 223 000	11	F/26	–	9.5
12	F/31	–	19.1	1 689 000	12	F/41	–	17.4
13	F/30	–	19.5	1 118 000	13	F/47	–	21.8

alphatradiol, prostaglandin analogues, retinoids, melatonin and corticosteroid), non-ablative fractional laser treatment, low-level laser therapy and hair transplantation.

Objective and subjective evaluations

Hair measurement was performed using a computerized hand-held USB camera PT system (Follioscope[®], LeedM Corporation, Seoul, Korea) at baseline and 3 and 6 months after the first treatment. Digital images of the hairs were obtained at 40-fold magnification at reference points by a phototrichogram scalp measurement method using a headband and a tapeline, and both the number and the thickness of hairs were measured with Follioscope PT[®] software (LeedM Corporation).¹⁹ The reference points included the 'P' (standard point), 'V' (Kang's point), and 'Fr' and 'Fl' points, as described in previous report.¹⁹ To calculate the baseline degree of disease progression and overall clinical improvement, a two-point scoring method with 'P' point (intersection of the posterior mid-sagittal line and the horizontal line connecting both upper ear roots; Fig. 1a, b) as a standard point and 'V' point (intersection of the mid-sagittal line and the coronal line connecting both tips of the tragus; Fig. 1c, d) as a diseased point were used following the formula below.

$$\frac{No (P) - No (V)}{No (P)} \times 50 + \frac{Th (P) - Th (V)}{Th (P)} \times 50 = \text{baseline degree of disease progression}(\%),$$

Where No (P) is the number of hairs measured at the 'P' point; No (V) is the number of hairs measured at the 'V' point; Th (P) is the mean thickness of hairs measured at the 'P' point; and Th (V) is the mean thickness of hairs measured at the 'V' point.

Six months after the first treatment, patients were asked to report the incidence and duration of side-effects of the treatment, including scalp oedema, blistering, bleeding, oozing, scaling or crusting, erythema or increased hair loss.

Flow cytometry

PRP preparation and the equal amount of whole blood were obtained from two healthy volunteers, who had provided informed consent, for cytometric analysis of CD34+ cells in peripheral blood. The surface staining of cellular components in PRP preparations was performed by staining with Cy7-conjugated anti-CD34 polyclonal antibody (Bioss, Woburn, MA, USA) at the concentration of 2 µg/mL. Fluorescence was detected with an LSRII (BD Bioscience, San Jose, CA, USA), and then standard

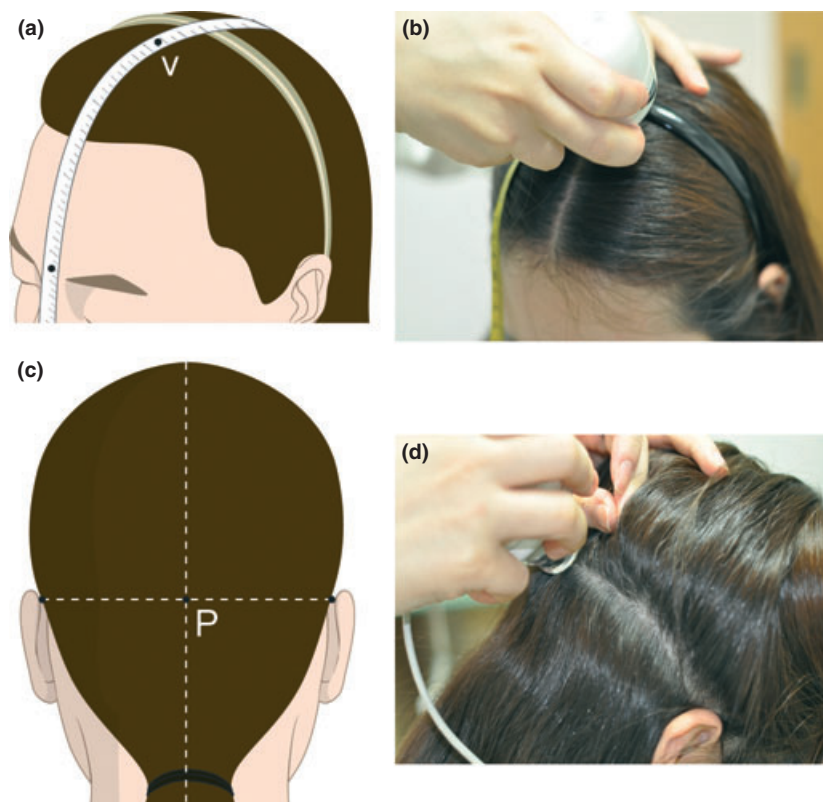


Figure 1 Photos demonstrating (a and b) 'V' point (intersection of the mid-sagittal line and the coronal line connecting both tips of the tragus) and (c and d) 'P' point (intersection of the posterior mid-sagittal line and the horizontal line connecting both upper ear roots).

acquisition and analysis of the data were obtained through FACS-Diva software version 6.1.3 (BD Bioscience).

Statistical analysis

The normality test was performed using Kolmogorov–Smirnov test, and significance differences were assessed by parametric criteria. Results were analysed by the MIXED procedure with Bonferroni post-hoc test, *t*-test and Chi-squared test using SAS software version 9.2 (SAS Institute Inc., Cary, NC, USA). Differences were considered statistically significant when the *P*-value was less than 0.05.

Results

Flow cytometry was performed using PRP preparation and an equal amount of peripheral blood in two healthy volunteers. One participant presented 6.7 cells/ μ L of CD34+ cells in peripheral blood, whereas those in the autologous PRP preparation were 31.1 cells/ μ L (Fig. 2a, b). The other participant presented 6.6 cells/ μ L of CD34+ cells in peripheral blood, whereas those in the autologous PRP preparation were 13.9 cells/ μ L (Fig. 2c, d).

At baseline, there were no statistical differences in hair count ($P > 0.05$), hair thickness ($P > 0.05$), or the degree of disease progression ($P > 0.05$) between the PRP treatment group and placental extract treatment group. The participants presented a mean degree of disease progression of 24.0 ± 11.0 in the PRP treatment group and 23.5 ± 10.1 in the placental extract treatment group, calculated by a two-point scoring method. Platelet counts in autol-

ogous PRP preparations, which were evaluated for each patient with PRP treatment, revealed a mean of $1,484,538.5 \pm 335,123.5$ platelets/ μ L (Table 1), whereas their peripheral blood had a mean of $241,750.0 \pm 37,051.1$ platelets/ μ L. Therefore, we obtained a mean 5.9-fold increase in concentrated platelets in autologous PRP preparation compared to the peripheral blood.

At 3 months after the first treatment, the patients treated with CD34+ cell-containing PRP presented clinical improvement of the mean number of hairs, $20.5 \pm 17.0\%$ ($P < 0.0001$); mean hair thickness, $31.3 \pm 30.1\%$ ($P < 0.0001$); and mean two-point scores, $84.4 \pm 51.7\%$ ($P < 0.0001$) compared with baseline values (Fig. 3). In patients treated with placental extracts, mean hair count ($14.7 \pm 11.9\%$, $P = 0.0015$), hair thickness ($14.5 \pm 13.8\%$, $P = 0.037$), and two-point score mean ($43.8 \pm 15.3\%$, $P < 0.0001$) were improved. The MIXED procedure revealed that CD34+ cell-containing PRP treatment presented a higher degree of improvement than placental extract treatment in two-point scores ($P = 0.018$), but not in hair thickness ($P > 0.05$) or hair count ($P > 0.05$) (Table 2).

At 6 months after the first treatment, the patients treated with CD34+ cell-containing PRP presented clinical improvement of mean hair count ($29.2 \pm 17.8\%$, $P < 0.0001$), mean hair thickness ($46.4 \pm 37.5\%$, $P < 0.0001$), and mean two-point score ($121.3 \pm 66.8\%$, $P < 0.0001$) compared with baseline (Fig. 4–6). In patients treated with placental extracts, mean hair count ($26.0 \pm 14.6\%$, $P < 0.0001$), hair thickness ($21.4 \pm 14.6\%$,

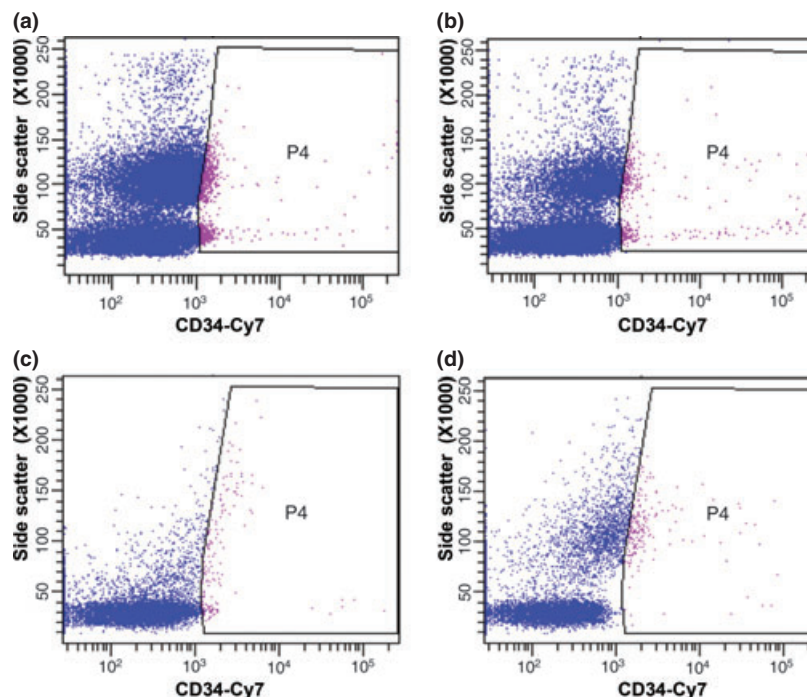


Figure 2 Flow cytometric analyses of Cy7-labelled mobilized CD34+ cells in (a, c) autologous platelet-rich plasma preparations and (b, d) the equal amount of peripheral blood.

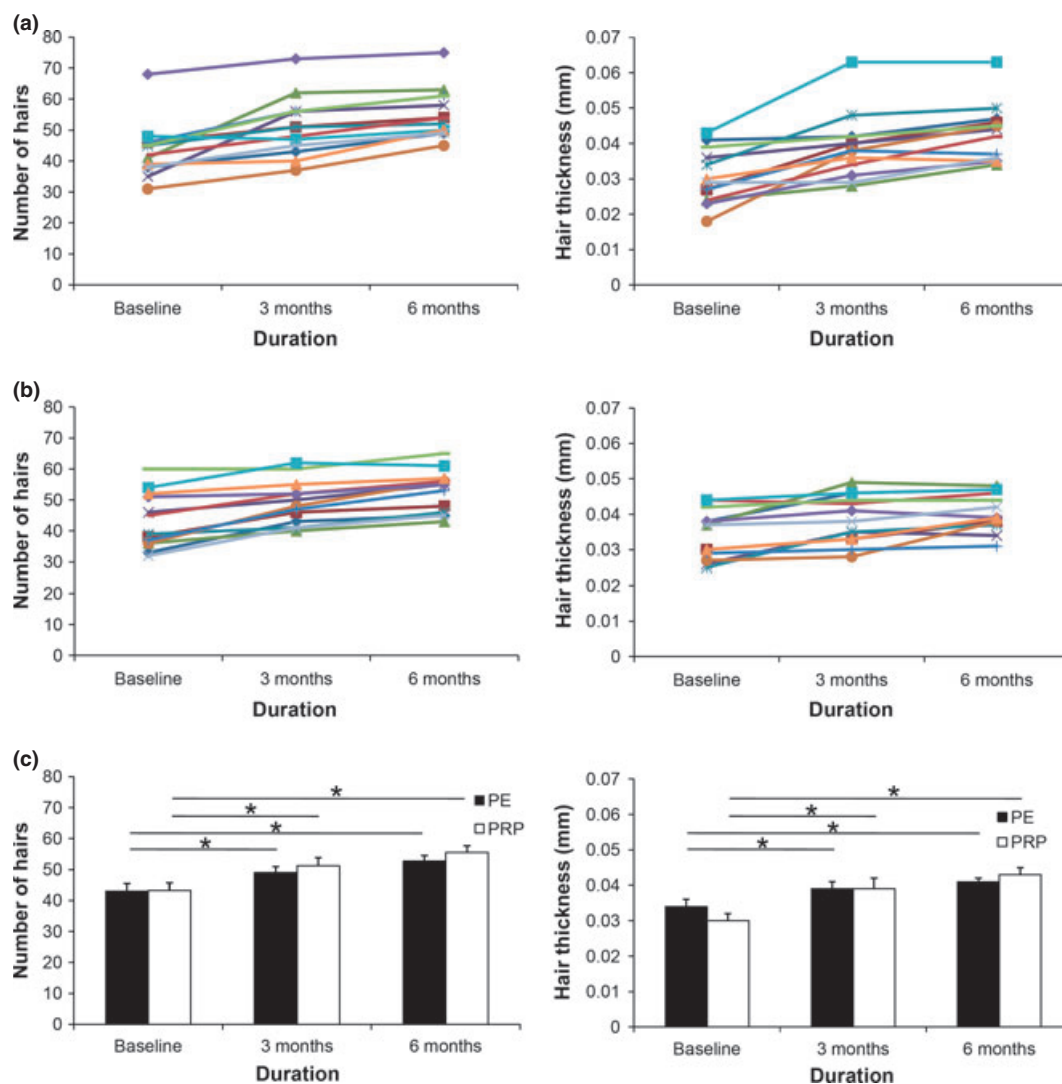


Figure 3 Computerized phototrichogram analyses of the thickness and number of hairs in patients with male and female pattern hair loss after treatment with interfollicular injection of (a) autologous CD34+ cell-containing platelet-rich plasma (PRP) preparation and (b) placental extracts (PE). (c) Clinical improvement after treatment with PRP and PE in the thickness and number of hairs presented as mean \pm standard error at 3 and 6 months. * $P < 0.05$.

$P = 0.001$), and two-point score ($72.8 \pm 15.0\%$, $P < 0.0001$) were improved compared with baseline. The MIXED procedure revealed that CD34+ cell-containing PRP treatment presented a higher degree of improvement than placental extract treatment in hair thickness ($P = 0.027$) and two-point score ($P = 0.023$), but not in hair count ($P > 0.05$) (Table 2).

Age, sex and concomitant treatment did not significantly affect hair count ($P > 0.05$), hair thickness ($P > 0.05$) or the degree of disease progression ($P > 0.05$) in either the PRP-treated group or the placental extract-treated group at 3 months or 6 months. In this study, side-effects of treatment included pain during the treatment with PRP treatment and placental extract treatment, transient post-treatment erythema and edema in the PRP treatment

group ($n = 3$; 23.1%) and folliculitis in the placental extract treatment group ($n = 1$; 7.7%). Other possible side-effects, such as secondary bacterial or viral infection, post-therapy blister formation, hypopigmentation, worsening of hair loss or scarring, were not observed.

Discussion

Current strategies for the treatment of pattern hair loss are mainly focussed on promoting cellular proliferation and differentiation during the hair growth cycle.¹⁰ Topical minoxidil promotes hair growth by stimulating epithelial cell mitosis and VEGF production as well as prolonging the anagen phase.¹⁰ Increased Bcl-2/Bax ratio and activated ERK and Akt by minoxidil reportedly promote

Table 2 Clinical efficacies of platelet-rich plasma preparation (PRP) treatment and placental extract (PE) treatment

	PRP treatment*	PE treatment*	P-value		
			Group	Time	Group × time
Hair count					
Baseline	43.2 ± 2.5	43.0 ± 2.5	<i>P</i> > 0.05	<i>P</i> < 0.0001	<i>P</i> > 0.05
3 months	51.2 ± 2.4	49.0 ± 2.4			
6 months	55.5 ± 2.1	52.7 ± 2.1			
Hair thickness					
Baseline	0.030 ± 0.002	0.034 ± 0.002	<i>P</i> > 0.05	<i>P</i> < 0.0001	<i>P</i> = 0.03
3 months	0.039 ± 0.002	0.039 ± 0.002			
6 months	0.043 ± 0.002	0.041 ± 0.002			
Two-point score					
Baseline	24.0 ± 2.9	23.5 ± 2.9	<i>P</i> > 0.05	<i>P</i> < 0.0001	<i>P</i> = 0.02
3 months	7.0 ± 2.4	13.3 ± 2.4			
6 months	-0.9 ± 1.8	6.8 ± 1.8			

*Data are presented as estimated mean ± standard error.

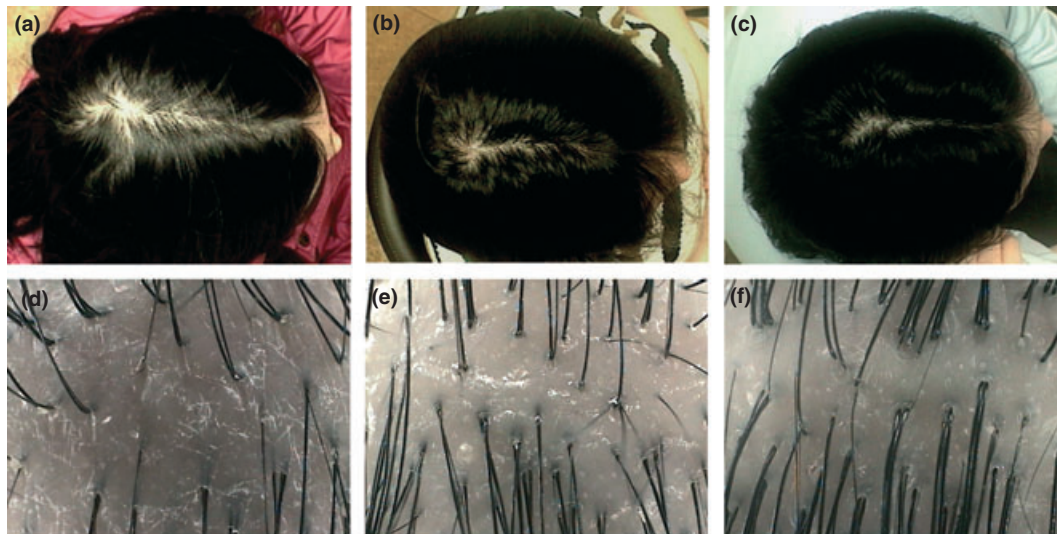


Figure 4 Digital images of the hairs on the 'V' point at (a–c) 1-fold magnification and (d–f) 40-fold magnification. Female pattern hair loss in a patient (4) (a, d) before, (b, e) 3 months after and (c, f) 6 months after interfollicular injection of autologous CD34+ cell-containing platelet-rich plasma preparation.

the survival of dermal papilla cells.²⁰ Oral finasteride also induces the prolongation of anagen hairs, which results in gradual thickening and elongation of the hairs.²¹ In addition, finasteride has been shown to reduce the pattern hair loss-associated increased expression of caspases and apoptosis inhibitors and therefore is ultimately suggested to activate anagen hair growth.^{22,23}

Anti-apoptotic effects of activated PRP have been suggested as one of the major contributing factors stimulating hair growth.^{2,24} PRP-induced activation of anti-apoptotic regulators, such as the Bcl-2 protein and Akt signalling, prolongs the survival of dermal papilla cells during the hair cycle.^{2,25} In addition, the up-regulation of FGF-7/ β -catenin signalling pathways with PRP treatment is suggested to stimulate hair growth by inducing follicular stem cell

differentiation as well as prolonging the anagen phase of the hair growth cycle.^{2,26}

In this study, SmartPREP[®]2 APC+[™] (Harvest Technologies Corp.) and SmartPREP[®]2 platelet concentrate systems (Harvest Technologies Corp.), approved by the US Food and Drug Administration, were used to prepare CD34+ cell-containing PRP. Although the platelet concentrations in the PRP preparations has not been optimized, preparations containing more than 1 000 000 platelets/ μ L are generally required for optimal results.^{2,27,28} In this study, platelet concentrations of each patient were evaluated before interfollicular injection and were found to have a mean of 1,484,538.5 ± 335,123.5 platelets/ μ L in the autologous PRP preparation, which was roughly a 6-fold greater concentrated platelet

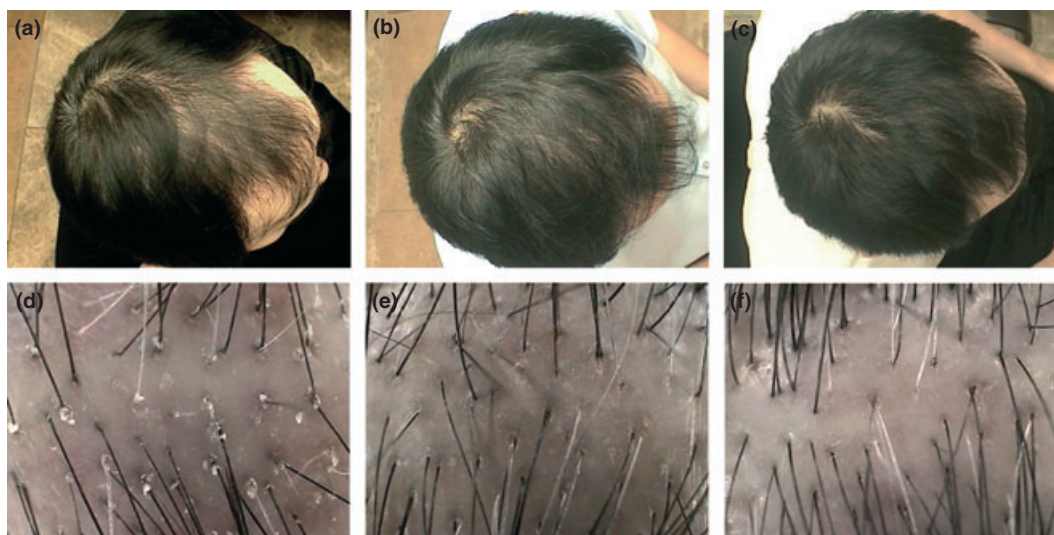


Figure 5 Digital images of the hairs on the 'V' point at (a–c) 1-fold magnification and (d–f) 40-fold magnification. Male pattern hair loss in a patient (7) (a, d) before, (b, e) 3 months after and (c, f) 6 months after interfollicular injection of autologous CD34+ cell-containing platelet-rich plasma preparation.

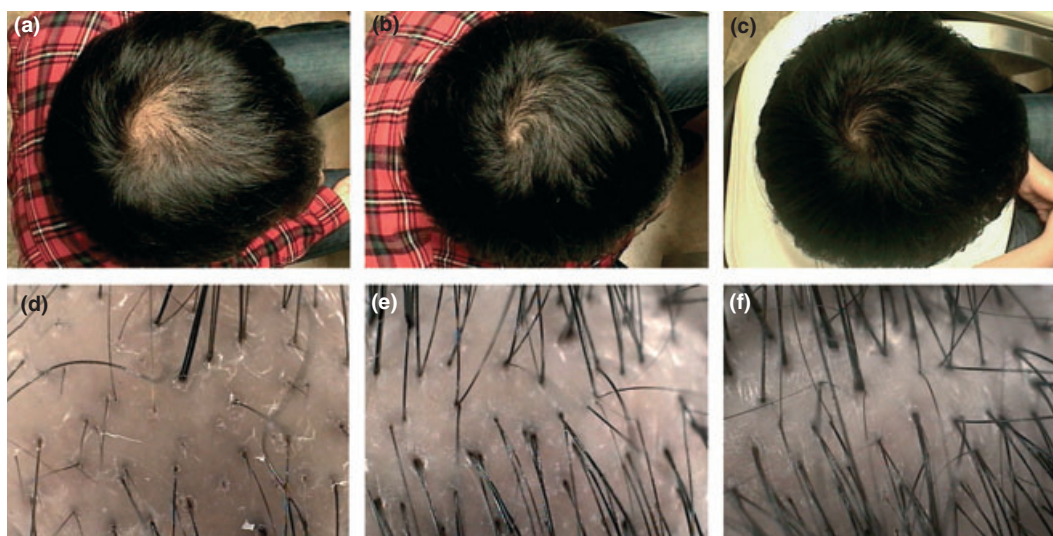


Figure 6 Digital images of the hairs on the 'V' point at (a–c) 1-fold magnification and (d–f) 40-fold magnification. Male pattern hair loss in a patient (8) (a, d) before, (b, e) 3 months after and (c, f) 6 months after interfollicular injection of autologous CD34+ cell-containing platelet-rich plasma preparation.

count compared to peripheral blood. We suggested that a sufficient number of platelets could be obtained in all patients by using an automated PRP preparation system. Giusti *et al.*²⁹ demonstrated that the optimal platelet concentration for the induction of angiogenesis in human endothelial cells was 1 500 000 platelets/ μL , whereas excessively high concentrations of platelets were suggested to decrease the angiogenic potential. In this study, a mean 1 484 555.6 platelets/ μL in the PRP preparation could effectively stimulate follicular and perifollicular angiogenesis, which is suggested to be one of the major factors in active hair growth.^{7,10}

The therapeutic use of autologous CD34+ haematopoietic stem cells has been proved to safely promote angiogenesis and vasculogenesis in ischemic conditions.^{12,30} Autologous bone marrow-derived CD34+ cell infusion to the infarct-related artery in patients with myocardial infarction showed significant therapeutic efficacies with ≥ 10 million CD34+ cells in a dose-dependent manner.³⁰ Recently, Zhong *et al.*³¹ presented that bone marrow aspirate concentrate had CD34+ cells of $7.2 \pm 6.9\%$, PRP preparation of $2.1 \pm 2.2\%$, and peripheral blood of $0.48 \pm 0.6\%$ by FACS analyses. Both human bone marrow aspirate concentrates and

CD34+ cell-containing PRP preparations provided therapeutic benefits in bone regeneration without significant differences between groups.³¹ In this study, CD34+ cell counts in PRP preparations varied from 13.9 cells/ μ L to 31.1 cells/ μ L, 2.1- and 4.7-fold more concentrated CD34+ cells compared to peripheral blood mononuclear cells respectively. We suggest that the interfollicular injection of concentrated mobilized CD34+ cells in PRP preparations could have synergistic effects on the PRP-induced angiogenesis in patients with male and female pattern hair loss.

Our data suggest that the interfollicular injection of autologous CD34+ cell-containing PRP preparations has a positive therapeutic effect on male and female pattern hair loss without remarkable major side-effects. However, the precise mechanisms of action of concentrated peripheral CD34+ cells in the hair growth cycling remain to be determined. Furthermore, optimized, prospective studies with a controlled/split scalp design should be conducted to confirm the clinical efficacies of CD34+ cells in patients with pattern hair loss.

Acknowledgement

We thank Hye Sun Lee, PhD (Department of Biostatistics, Yonsei University College of Medicine, Seoul, Korea) for her help with the statistical analyses and Dong-Su Jang (Medical Illustrator, Medical Research Support Section, Yonsei University College of Medicine, Seoul, Korea) for his help with the figures.

References

- Takikawa M, Nakamura S, Nakamura S *et al.* Enhanced effect of platelet-rich plasma containing a new carrier on hair growth. *Dermatol Surg* 2011; **37**: 1721–1729.
- Li ZJ, Choi HI, Choi DK *et al.* Autologous platelet-rich plasma: a potential therapeutic tool for promoting hair growth. *Dermatol Surg* 2012; **38**: 1040–1046.
- Marx RE. Platelet-rich plasma: evidence to support its use. *J Oral Maxillofac Surg* 2004; **62**: 489–496.
- Eppley BL, Pietrzak WS, Blanton M. Platelet-rich plasma: a review of biology and applications in plastic surgery. *Plast Reconstr Surg* 2006; **118**: e147–e159.
- Merkx MA, Fennis JP, Verhagen CM, Stoeltinga PJ. Reconstruction of the mandible using preshaped 2.3 mm titanium plates, autogenous particulate cortico-cancellous bone grafts and platelet rich plasma: a report on eight patients. *Int J Oral Maxillofac Surg* 2004; **33**: 733–739.
- Uebel CO, da Silva JB, Cantarelli D, Martins P. The role of platelet plasma growth factors in male pattern baldness surgery. *Plast Reconstr Surg* 2006; **118**: 1458–1466.
- Mecklenburg L, Tobin DJ, Müller-Röver S *et al.* Active hair growth (anagen) is associated with angiogenesis. *J Invest Dermatol* 2000; **114**: 909–916.
- Lachgar S, Moukadiri H, Jonca F *et al.* Vascular endothelial growth factor is an autocrine growth factor for hair dermal papilla cells. *J Invest Dermatol* 1996; **106**: 17–23.
- Kozłowska U, Blume-Peytavi U, Kodelja V *et al.* Expression of vascular endothelial growth factor (VEGF) in various compartments of the human hair follicle. *Arch Dermatol Res* 1998; **290**: 661–668.
- Semalty M, Semalty A, Joshi GP, Rawat MS. Hair growth and rejuvenation: an overview. *J Dermatolog Treat* 2011; **22**: 123–132.
- Li W, Enomoto M, Ukegawa M *et al.* Subcutaneous injections of platelet-rich plasma into skin flaps modulate proangiogenic gene expression and improve survival rates. *Plast Reconstr Surg* 2012; **129**: 858–866.
- Mackie AR, Klyachko E, Thorne T *et al.* Sonic hedgehog-modified human CD34+ cells preserve cardiac function after acute myocardial infarction. *Circ Res* 2012; **111**: 312–321.
- Jujo K, Ii M, Losordo DW. Endothelial progenitor cells in neovascularization of infarcted myocardium. *J Mol Cell Cardiol* 2008; **45**: 530–544.
- Kong MH, Lee EJ, Lee SY, Cho SJ, Hong YS, Park SB. Effect of human placental extract on menopausal symptoms, fatigue, and risk factors for cardiovascular disease in middle-aged Korean women. *Menopause* 2008; **15**: 296–303.
- Pal P, Mallick S, Mandal SK *et al.* A human placental extract: *in vivo* and *in vitro* assessments of its melanocyte growth and pigment-inducing activities. *Int J Dermatol* 2002; **41**: 760–767.
- Tonello G, Daglio M, Zaccarelli N *et al.* Characterization and quantitation of the active polynucleotide fraction (PDRN) from human placenta, a tissue repair stimulating agent. *J Pharm Biomed Anal* 1996; **14**: 1555–1560.
- Park SY, Phark S, Lee M, Lim JY, Sul D. Anti-oxidative and anti-inflammatory activities of placental extracts in benzo[a]pyrene-exposed rats. *Placenta* 2010; **31**: 873–879.
- Moftah N, Moftah N, Abd-Elaziz G *et al.* Mesotherapy using dutasteride-containing preparation in treatment of female pattern hair loss: photographic, morphometric and ultrastructural evaluation. *J Eur Acad Dermatol Venereol* 2012; doi: 10.1111/j.1468-3083.2012.04535.x. [Epub ahead of print].
- Lee EH, Kang JS, Kang DS *et al.* Facilitated scalp measuring using phototrichogram with a headband and tapeline. *Dermatol Surg* 2011; **37**: 1150–1152.
- Han JH, Kwon OS, Chung JH *et al.* Effect of minoxidil on proliferation and apoptosis in dermal papilla cells of human hair follicle. *J Dermatol Sci* 2004; **34**: 91–98.
- Tosti A, Piraccini BM. Finasteride and the hair cycle. *J Am Acad Dermatol* 2000; **42**: 848–849.
- Sawaya ME, Blume-Peytavi U, Mullins DL *et al.* Effects of finasteride on apoptosis and regulation of the human hair cycle. *J Cutan Med Surg* 2002; **6**: 1–9.
- de Rivero Vaccari JP, Sawaya ME, Brand F 3rd *et al.* Caspase-1 level is higher in the scalp in androgenetic alopecia. *Dermatol Surg* 2012; **38**: 1033–1039.
- Ferraris C, Cooklis M, Polakowska RR, Hakke AR. Induction of apoptosis through the PKC pathway in cultured dermal papilla fibroblasts. *Exp Cell Res* 1997; **234**: 37–46.
- Kwon OS, Pyo HK, Oh YJ *et al.* Promotive effect of minoxidil combined with all-trans retinoic acid (tretinoin) on human hair growth *in vitro*. *J Korean Med Sci* 2007; **22**: 283–289.
- Sohn KC, Shi G, Jang S *et al.* Pitx2, a β -catenin regulated transcription factor, regulates the differentiation of outer root sheath cells cultured *in vitro*. *J Dermatol Sci* 2009; **54**: 6–11.
- Landesberg R, Roy M, Glickman RS. Quantification of growth factor levels using a simplified method of platelet-rich plasma gel preparation. *J Oral Maxillofac Surg* 2000; **58**: 297–301.
- Weibrich G, Kleis WK, Hafner G. Growth factor levels in the platelet-rich plasma produced by 2 different methods: curasan-type PRP kit versus PCCS PRP system. *Int J Oral Maxillofac Implants* 2002; **17**: 184–190.
- Giusti I, Rughetti A, D'Ascenzo S *et al.* Identification of an optimal concentration of platelet gel for promoting angiogenesis in human endothelial cells. *Transfusion* 2009; **49**: 771–778.
- Quyyumi AA, Waller EK, Murrow J *et al.* CD34+ cell infusion after ST elevation myocardial infarction is associated with improved perfusion and is dose dependent. *Am Heart J* 2011; **161**: 98–105.
- Zhong W, Sumita Y, Ohba S *et al.* *In vivo* comparison of the bone regeneration capability of human bone marrow concentrates vs. platelet-rich plasma. *PLoS ONE* 2012; **7**: e40833.